

# Reproductive Anatomy of the Cow/Heifer

A basic introduction to the components of the reproductive tract with discussion about their importance in managing cows and heifers

Courtne Carter, Beef Program Coordinator and Graduate Student  
Justin Rhinehart, Associate Professor and Extension Specialist  
Department of Animal Science

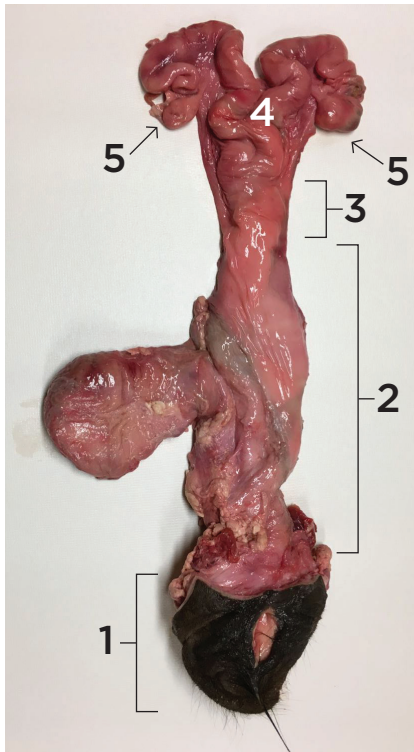Understanding reproductive anatomy is critical to understanding reproductive management strategies. Think about the reproductive tract as a system of biological tubes that are designed to accomplish all the tasks required to create a new calf from conception to calving. The tubing looks different in areas that accomplish specific tasks, so each section of tubing has a unique name.

Here is a list of the names for each section shown in Figure 1 with the corresponding number. Figure 2 provides an internal view of the same structures.

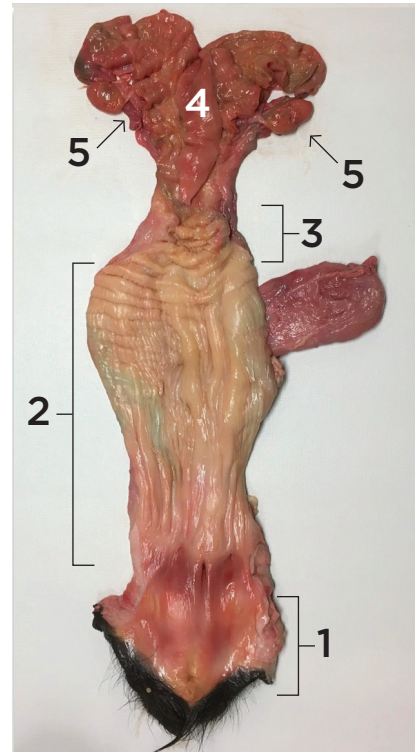
1. Vulva  
2. Vagina

3. Cervix  
4. Uterus

5. Ovaries



**Figure 1:** Heifer reproductive tract with other tissue removed to display the anatomy.



**Figure 2:** The same heifer reproductive tract as in Figure 1, opened to display the inner components of this "system of tubes."

An important feature of the cow/heifer reproductive tract is its location. Manipulation of the reproductive tract for various management practices, such as rectal palpation for pregnancy diagnosis or artificial insemination, is possible because the reproductive tract is positioned immediately underneath, and runs parallel to, the exit of the digestive tract (rectum). The following sections provide more details about each anatomical structure of the cow/heifer reproductive tract with emphasis on the traits important to making reproductive management decisions.

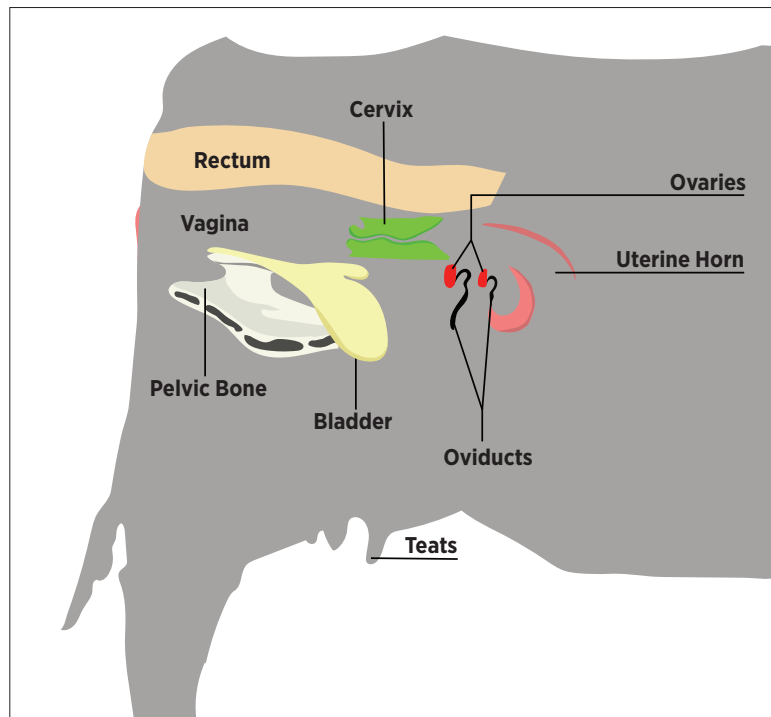


Figure 3: Cow silhouette showing location of the reproductive tract

## Vulva

The outermost portion of the reproductive tract is the vulva. This structure protects the reproductive tract by keeping out larger debris. Although the vulva is a relatively small portion of the entire tract, its visibility provides clues to what might be occurring in the rest of the tubing system. For instance, it becomes swollen and displays more movement when a heifer or cow approaches calving – this is often referred to as “springing.” The swelling and movement indicate similar structural changes are happening within the rest of the system to prepare for calving. A swollen vulva and mucus discharge can be indicators of estrus and assist in the application of reproductive technologies such as artificial insemination and embryo transfer.

## Vagina

The area from the vulva to the beginning of the cervix is known as the vagina. The vagina receives the bull’s penis during natural mating, and semen is deposited near the entrance of the cervix. The fornix vagina is a 360-degree pocket that surrounds the opening of the cervix. It functions to hold semen for a short amount of time as it is pulled into the cervix by contractions and moves through the other components of the tubular tract. In artificial insemination, the fornix vagina is often referred to as the “blind pocket” and can be a difficult obstacle when attempting to insert an insemination rod into the cervical os (entrance of the cervix; Figure 4).

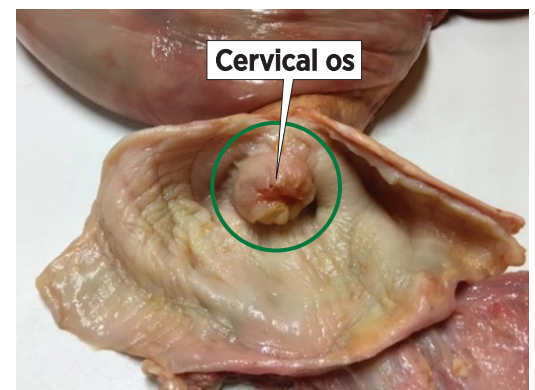


Figure 4: Fornix vagina (green circle) and the Cervical os (entrance to the cervix).

## Cervix

The cervix acts as a line of defense between the vagina and uterus. It can be thought of as a narrow, difficult to navigate passage that helps keep foreign material from entering the uterus from the vagina. The cervix is tightly closed when the cow or heifer is pregnant, and a thick mucus is produced to protect the developing fetus and/or uterus from outside environmental materials. The cervix has protruding internal folds that interlock to further aid in protection of the uterus (Figure 5; sometimes called “rings”). This passageway dilates when the cow or heifer is in heat and the mucus thins to aide in moving sperm through the tract.

## Uterus

The uterus in cattle is composed of three distinct regions: the uterine body and two uterine horns. Following the cervix, the uterine body remains a single tube. The uterine body is approximately 1 inch in length and functions as a “common area” of the two uterine horns that follow. When performing artificial insemination, the uterine body is the optimal point of sperm deposition.

The end of the uterine body is marked by a divide where the tube system splits into a mirror image pair of each structure. The paired components include uterine horns, oviducts and the ovaries. Together, the uterine body and two uterine horns make a “Y” shape. The point at which the horns begin to fork can be felt when palpating the tract and is often referred to as the external bifurcation. The uterine horns support sperm transportation to the oviducts and are the site for fetal growth and development during pregnancy.

Each uterine horn has structures along the inner lining called caruncles. Structures on the placenta called cotyledons attach to these areas during pregnancy (Figure 6). When the caruncles and cotyledons are fused together, they are called placentomes. These areas can be easily recognized by palpation throughout mid- to late pregnancy and their presence or absence can be used to help diagnose pregnancy status. Blood vessels in these areas transfer nutrients from the dam’s blood into the placenta, which are then carried into the fetus through the umbilical cord to support growth and development of the fetus. Similarly, waste products in the fetus’ blood are carried out through the placentomes into the dam’s blood.

Figure 6: The left image shows placenta removed from the uterus to show the cotyledons. Note the blood vessels leading to and from each structure; they carry the fetus’ blood to and from the umbilical cord to pick up nutrients from the dam and dispose of waste. The right image shows caruncles on the inside lining of the uterus.

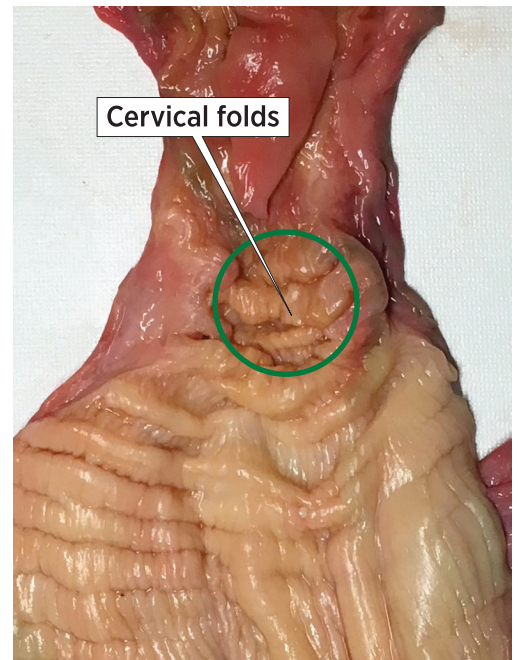


Figure 5: Internal view of the cervix displaying the internal folds or “rings.”

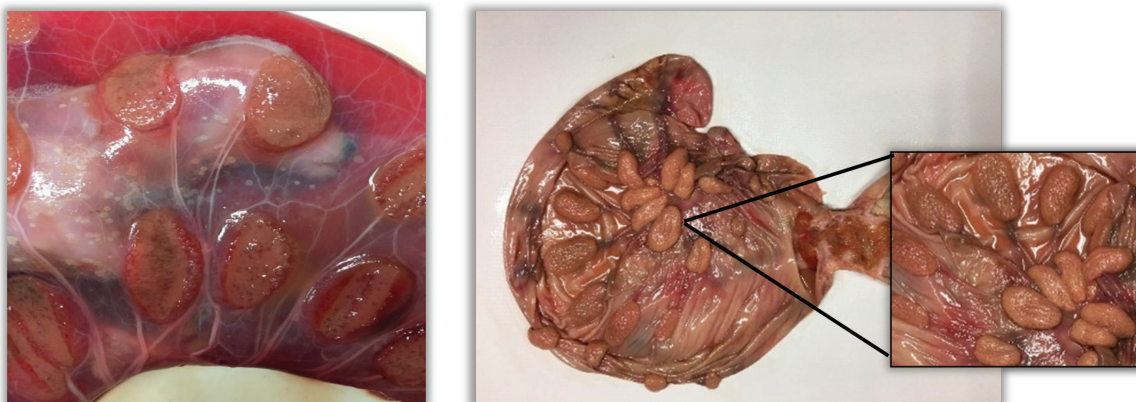


Figure 6: Placenta removed from the uterus to show the cotyledons (note the blood vessels leading to and from each structure; they carry the fetus’ blood to and from the umbilical cord to pick up nutrients and dispose of waste). The right image shows caruncles on the inside lining of the uterus.

## Oviducts

Continuing through the reproductive tract, the oviducts are connected to the ends of each uterine horn and function as a bridge between the uterine horn and the ovary (Figure 7). Several important things happen in the oviduct that lead to fertilization. The new embryo remains in the oviduct for about 6-7 days. The oviducts are divided into three different segments: the infundibulum, ampulla and isthmus. The infundibulum can be viewed as a funnel, not only due to its shape but also its function to catch the oocyte when ovulation of a follicle occurs. The ampulla makes up the middle portion of the oviduct, and functions to move the oocyte to be fertilized. Fertilization occurs in the oviduct at the ampullary-isthmus junction. The isthmus is the final segment of the oviduct that connects to the uterine horns.

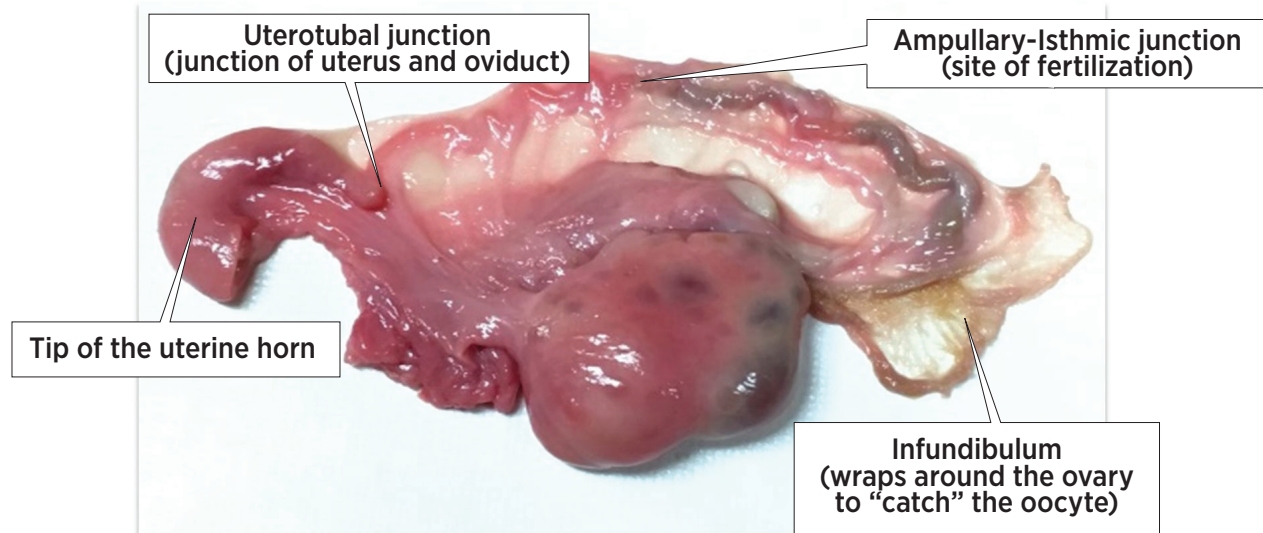


Figure 7: An ovary and oviduct with surrounding connective tissue.

## Ovaries

The ovaries are components of the tract that are not tubular. They house the oocytes, often called eggs, which will be released and move into the oviduct to be fertilized. From there, they become the embryo that develops into a fetus and eventually becomes a newborn calf. The ovaries are also responsible for making hormones that are important for maintaining either pregnancy or normal estrous cycles. Figures 8 and 9 show the general shape and size of the ovaries with two major structures: a follicle, and a corpus luteum, respectively.

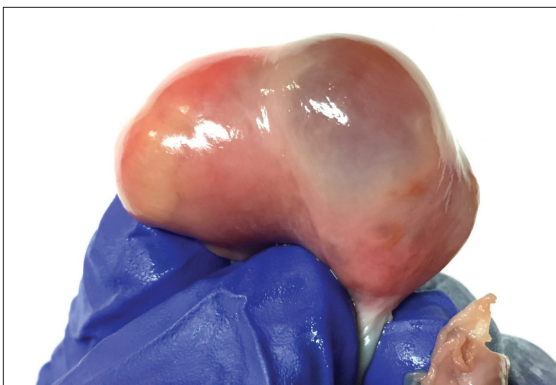

Figure 8: An ovary with a dominant follicle present.

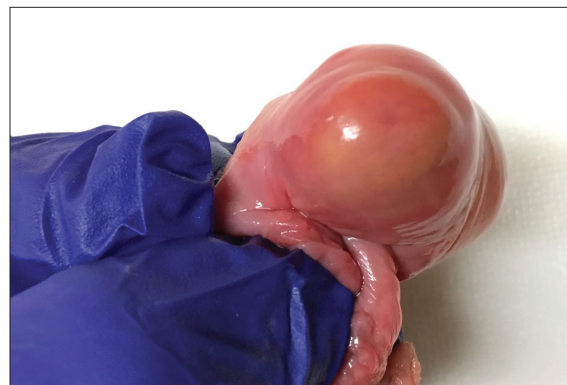

Figure 9: An ovary with a corpus luteum (CL) present.

The basic knowledge of the cow and heifer reproductive anatomy described in this publication will make the purposes of various reproductive management practices easier to understand. In turn, understanding the importance of reproductive technologies, such as artificial insemination, embryo transfer and reproductive ultrasound will lead to better decision making and implementation by cattle producers.



[UTIA.TENNESSEE.EDU](http://UTIA.TENNESSEE.EDU)

Real. Life. Solutions.™